



ANIMAL PHYSIOTHERAPY SOLUTIONS

Cranial Cruciate Ligament Injuries

What is The Cranial Cruciate Ligament?

This ligament is found deep within the stifle (Knee) joint and has a vital role in providing stability especially during the stance (weight bearing) phase of gait. During weight bearing it prevents forward movement of the lower part of the hind leg (Tibia) on the upper part of the limb (femur). Although additional stability of the stifle joint is provided by the surrounding musculature and the menisci (Cartilages), damage to the cranial cruciate ligament can lead to ongoing pain and dysfunction.

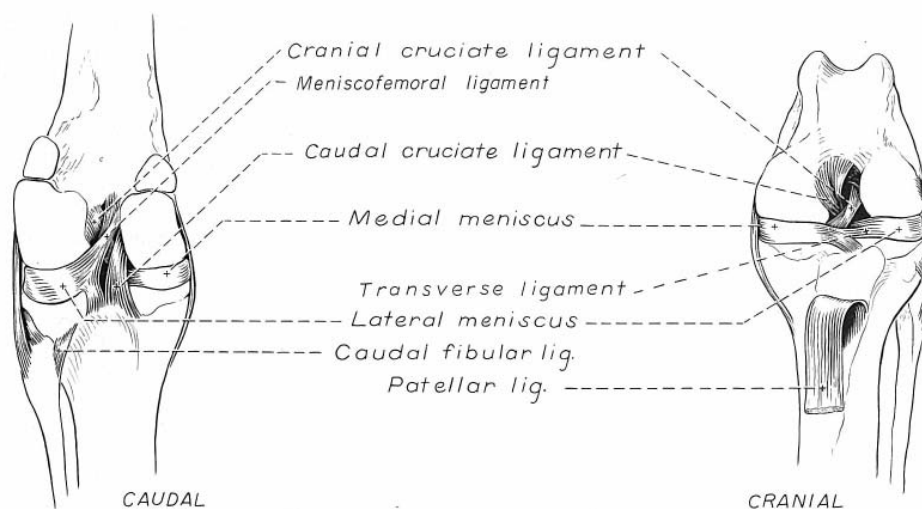


Figure 5-24. Ligaments of left stifle joint.

(Caudal view, looking from the back of the knee. Cranial view, looking from the front of the knee.)

Partial or full rupture of this ligament is one of the most common injuries affecting many breeds of dogs and may occur due to trauma/ sporting injury or more commonly from degenerative changes occurring within the fibres of the ligament itself.

An acute injury presents as a sudden onset of pain and swelling resulting in significant hind limb lameness. Partial ruptures however can have a more insidious onset with intermittent pain, swelling and lameness which is often exacerbated by exercise. The instability caused by both an acute rupture and the more chronic partial rupture will lead to degenerative joint disease (Arthritis) due to the increased 'wear and tear' on the joint surfaces.

Treatment:

There are many different treatment techniques for this condition and the choice is often dependent on size and weight of the animal, the degree of joint instability and degenerative changes (Arthritis) already occurred.

Conservative treatment can occasionally be used to treat some small dogs; however for most animals the treatment of choice is surgical stabilisation of which there are several different techniques.

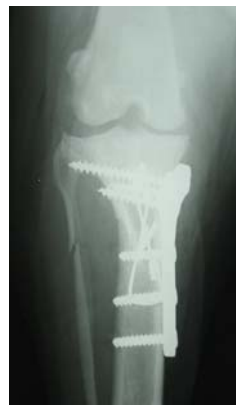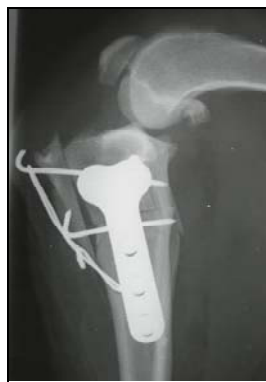Cranial Cruciate Repairs:

- *Extracapsular Repair (Modified De Angelis Repair)*

This is a technique that can be used in smaller dogs. It provides stability of the stifle joint by the use of a nylon prosthesis mimicking the Cranial Cruciate ligament. This technique is not usually recommended for large dogs or those with steep tibial plateau angles. The tibial Plateau angle is the angle of the weight bearing surface of the tibia.

- *Tibial Plateau Levelling Osteotomy/ Tibial wedge Osteotomy (TPLO/TWO)*

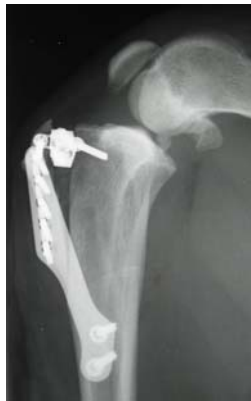These techniques do not replace the cranial cruciate ligament but alter the angle of the weight bearing surface of the knee (Tibial Plateau). Multiple osteotomies (bone cuts) are performed to alter the shape and position of the joint, correcting the abnormal biomechanical forces, eliminating the need for the cranial cruciate ligament



Tibial Plateau Leveling Osteotomy (TPLO)

- *Tibial Tuberosity Advancement (TTA)*

This is similar to the TPLO in that it uses an osteotomy (bone cut) to alter the stifle's (Knee joints) biomechanics to regain stability of the joint. It does this by repositioning the attachment of the patella tendon. Once repositioned it is held in place with a titanium cage, plate and screws.



Tibial Tuberosity
Advancement

With both the TPLO and TTA surgeries, the bone cuts (osteotomies) are held secure with plates and screws until the body repairs the area by laying down new bone. Although post operative x-rays are often taken between 6-8 weeks post surgery to confirm that healing is progressing, complete bony healing can take approximately 12 weeks. Therefore during the first 6-8 weeks your pet must be confined with controlled exercise only. Free off leash running should not be allowed until your vet has reviewed your pet's condition at approximately 12-18 weeks.

Post Operative Care:

Your pet's post operative care will depend on your surgeon's protocols. Hopefully you will be given some post operative instructions, if not please clarify with your vet when you can commence physiotherapy.

CONFINEMENT:

As previously mentioned your pet should be confined to a small room where they can not run, jump or fall. Do not allow your pet to run between rooms or up and down hall ways, climb stairs, jump on and off furniture, or play with other pets.

EXERCISE:

All exercise should be controlled on leash walking according to your pet's discharge or Physiotherapy instructions.

MEDICATION:

A non-steroidal anti-inflammatory is often prescribed initially following surgery to help reduce both pain and inflammation.

REVISITS:

This is again dependent on your surgeon's protocols. Following the initial post operative check/bandage removal your surgeon may not need to see your pet until approximately 6-8 weeks post operatively. At this time recheck x-rays may be taken.

PHYSIOTHERAPY:

The specialist surgeons at Veterinary Specialist Services highly recommend physiotherapy as an important part of your pet's rehabilitation following cruciate injuries. Treatment can commence as early as day one post operatively however if a Robert Jones bandage has been applied then treatment commences at bandage removal, approximately 5-7 days post operatively.



A Robert Jones Bandage is often applied post operatively

On the initial consultation a thorough assessment of the animal's condition allows the physiotherapist to formulate an individually designed treatment program. This consists of 'hands on' treatment techniques and home exercise program, consisting of gentle mobilisation and strengthening exercises and a slow pace on lead controlled walking program.

To ensure the best possible rehabilitation following surgery, physiotherapy should continue weekly or fortnightly throughout the first 6-8 weeks post surgery.

This treatment will include gait re-education, treatment of any secondary soreness, and continual assessment of the animal's progress and appropriate progression of their home exercise program. Hydrotherapy using the under water treadmill also forms part of many animals rehabilitation and can commence once the incision has healed.

For further information on physiotherapy please contact Lindsey Connell on 0403 970 675 or by Email; animalphysio@animalphysio.net